

# An Ultraconservative Technique for Restoring a Missing Central Incisor



Richard M. Parker, DDS, FAGD

Private Practice  
Lemont, Illinois  
Phone: 630.257.1010  
Web site:  
[www.parker-dental.com](http://www.parker-dental.com)

## Abstract

Replacing a missing anterior tooth involves addressing a variety of functional, biological, and esthetic factors to achieve a lifelike restoration. In addition, practitioners must understand and take into consideration the patient's wants and desires to satisfy his or her expectations. This article presents a case in which an avulsed central incisor is restored with an ultraconservative, fixed prosthesis. In addition, soft-tissue development and contouring of a pontic site will be discussed as it pertains to overall esthetics.

It has been said that restoring a missing single central incisor is one of the most difficult esthetic procedures in dentistry. A variety of dental concerns need to be addressed when treating an anterior tooth such as shade (hue, chroma, and value), morphology, gingival contours, bone levels, and occlusion. Additionally, a choice between a fixed prosthesis, removable prosthesis, and an implant needs to be determined. Finally, patients are not only becoming more demanding with regard to esthetics, but also are often opting for more conservative and less invasive procedures (ie, more tooth preservation).

## Case Presentation

A 22-year-old man presented for emergency treatment of an avulsed left central incisor (tooth No. 9). The tooth was traumatically lost nearly 12 hours before and the patient did not possess the tooth. An oral examination, basic central nervous system

evaluation, and necessary radiographs were performed. The patient was not experiencing any pain and did not have any hard- or soft-tissue injuries that required treatment other than the area of tooth No. 9. His primary concern was to "have something to fill in the space immediately."

The young man also had an existing crossbite between teeth Nos. 10 and 23, so impressions for a Hawley-type appliance were taken to not only replace tooth No. 9, but also to correct the anterior crossbite. The interim prosthesis was delivered to the patient the next day. The appliance had acrylic on the maxillary posterior teeth to open the bite to allow movement of tooth No. 10, a screw mechanism on the palatal of tooth No. 10 to move it facially, and a labial arch wire.

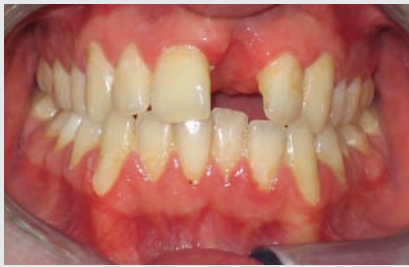## Diagnosis

The preoperative appearance of the avulsion site after healing exhibit-

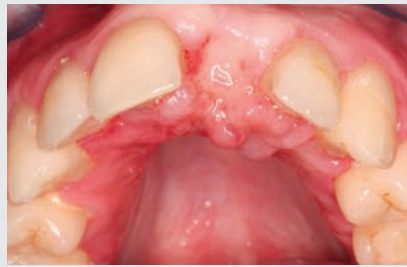ed an extensive dished-out appearance of the buccal plate (Figure 1). The corresponding radiograph of the area not only indicated loss of the buccal plate, but also loss in bone level height. A large portion of the buccal plate and a portion of the coronal palatal bone were avulsed along with the tooth. The patient was referred to a periodontist for a consultation. It was determined, because of the unreliability of increasing vertical bone height with grafting,<sup>1</sup> that the use of an implant to replace tooth No. 9 had to be eliminated because of esthetic concerns. The patient had 2 requests in regard to his treatment: he did not want a removable partial denture and he did not want his "teeth ground down."

## Treatment Plan

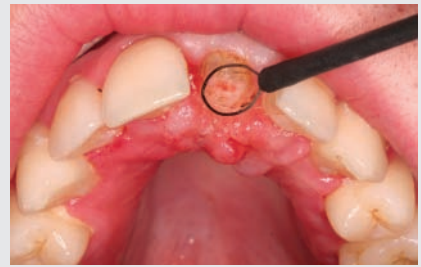The following treatment plan was developed after carefully considering the clinical factors and the patient's goals. Because an implant was not esthetically feasible, and a removable partial denture would not be acceptable to the patient, the only choice remaining would be a fixed prosthesis. A fixed, bonded bridge (Maryland bridge) would be used to replace the missing central incisor as it would fulfill the patient's criteria to be nonremovable and would not require tooth reduction.



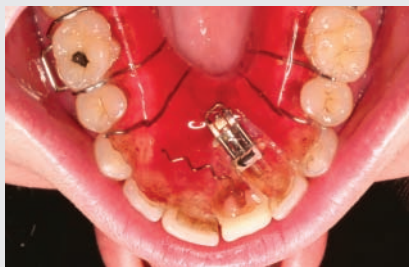**Figure 1**—Retracted view after orthodontic alignment of tooth No. 10 and before connective tissue graft.



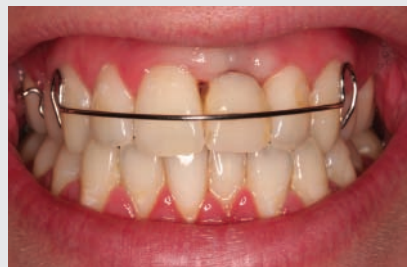**Figure 2**—After connective tissue graft in the area of tooth No. 9.



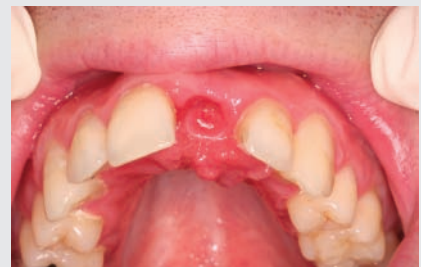**Figure 3**—Electrosurgery recontouring of pontic site.



**Figure 4**—Interim removable partial denture in place.



**Figure 5**—Initial placement of denture tooth into pontic site after electro-surgical contouring of soft-tissue graft; note slight blanching of gingival.



**Figure 6**—Healing of pontic site after initial tissue contouring.

Resin bonded bridges have had a reputation for unreliability because of debonding<sup>2</sup>; however, proper case selection is essential to ensure success with this type of prosthesis. The patient met all the requirements for a Maryland bridge, including short span, anterior location, adequate clearance, lack of deep overbite, immobile teeth, adequate enamel, and lack of parafunctional habits.

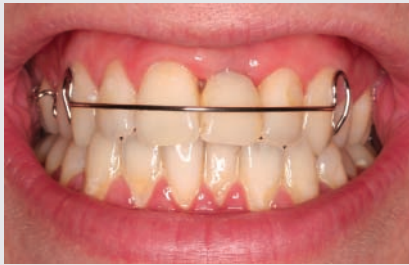A soft-tissue, connective tissue graft would be needed to augment the gingiva in the area of tooth No. 9. This would be done after the left lateral incisor was moved out of crossbite and into proper position. The pontic site would then be shaped and the gingival tissue would develop over several months before placement of the final restoration.

### **Gingival Development**

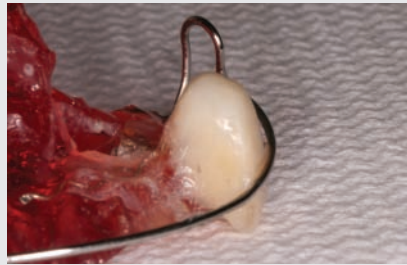After the orthodontic positioning of tooth No. 10, a connective tissue graft was performed in the area of tooth No. 9 (Figure 2). After the grafting procedure, the buccal contour was still a bit deficient. The area was prepared (Figure 3) for a biconvex or egg-shaped pontic via the use of an electro-surgery unit (Sensimatic 500SE, Parkell, Inc). On the interim appliance (Figure 4), the denture tooth was contoured with acrylic (SNAP, Parkell, Inc) to fit into the pontic site. The tooth was over-contoured slightly and was then polished and placed into position (Figure 5). Immediately on placement, the tissue should show blanching indicating that the denture tooth is in firm contact with the tissue, which helps the tissue maintain its shape. The blanching should only last for about 15 seconds.<sup>3</sup>

To maintain and develop tissue contours, the patient was instructed to wear the interim appliance 24 hours a day and to remove it only for hygiene purposes. Three weeks later, the pontic site was healed (Figure 6), but esthetically the facial-gingival portion of the denture tooth was deficient (Figure 7). The soft tissue was not sculpted at this appointment, but the denture tooth was recontoured for esthetics (Figure 8). Again when the appliance was seated, slight transient tissue blanching occurred (Figure 9).

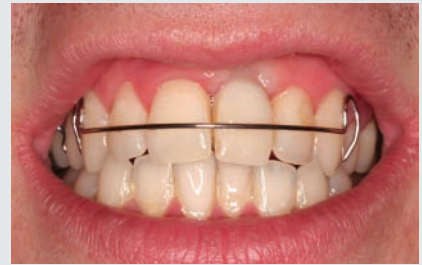
Approximately 3 weeks later, further tissue contouring was performed with electro-surgery (Figure 10) to move the pontic site slightly palatal because the buccal gingiva was too thin. If the gingiva is too thin, it can recede from the pontic and cause an esthetic concern. The denture tooth



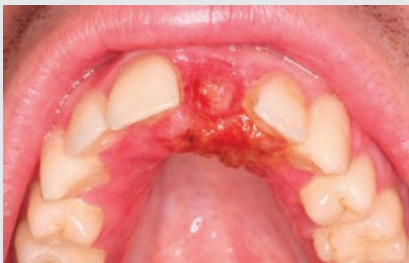**Figure 7**—Healing complete after initial soft-tissue contouring; denture tooth and gingival need additional shaping for esthetics.



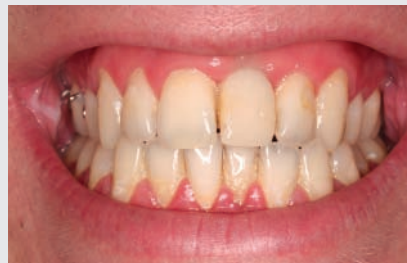**Figure 8**—Additional shaping of denture tooth with acrylic (side view).



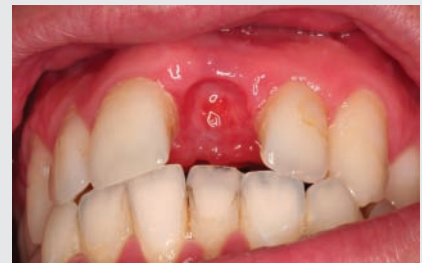**Figure 9**—Placement of maxillary partial denture after additional shaping of denture tooth; again note transient tissue blanching.



**Figure 10**—Final electro-surgical contouring of soft tissue at pontic site and on palate.



**Figure 11**—Final maturation of tissue around interim pontic.



**Figure 12**—Close-up of pontic site; note bi-concave contours.

was shaped to angle the gingival-facial surface toward the palate and acrylic was added to slightly widen the tooth at the papilla level. These adjustments gave the central incisors similar gingival heights and provided more support for the papilla.

### **Prosthetic Placement**

Figures 11 and 12 show the matured gingival tissue that has developed well around the interim denture tooth. The shape and contours of the denture tooth are esthetically satisfactory. Fabrication of the final prosthesis can now proceed. A shade was taken for the final prosthesis with the Vita Easyshade (Vident), and digital photos (Figure 13) of Vita 3D shade tabs (Vident) were e-mailed to the laboratory.

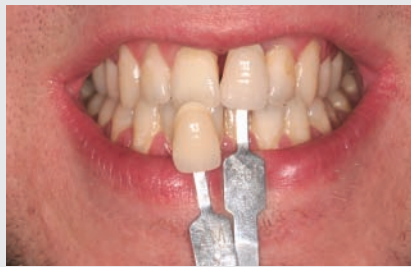Tooth preparation was kept to a minimum, as there was plenty of clear-

ance for the metal wings of the bridge. This is because there was only a 1.5 mm overbite and the incisors were out of occlusion by 0.5 mm. This also allowed for adequate thickness of the casting that would prevent any flex during function. The only preparations done on teeth Nos. 8 and 10 were cylindrical cuts into the cingulum area of each tooth (Figure 14). Because the main force vectors in the maxillary anterior were in an apical and labial direction, retentive slots would help resist dislodgement of the prosthesis from the apical-labial torque that would be applied during mastication.<sup>4</sup>

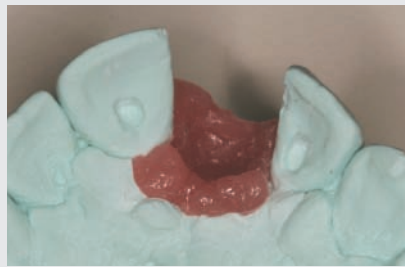The laboratory technician was instructed to keep the metal wings of the prosthesis off the incisal third to prevent darkening of the tooth because of the inhibition of light transmission. In addition, care was taken to make

sure metal would not be visible interproximally or at the embrasure areas. The patient continued to wear the interim appliance 24 hours a day, taking it out only for oral hygiene purposes, to maintain the tissue contours at the pontic site.

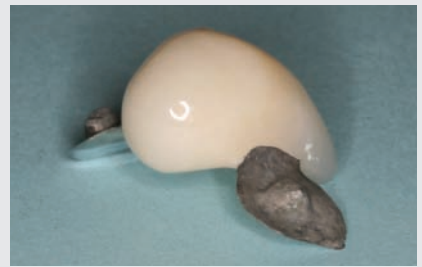The final prosthesis (Figures 15 and 16) was fabricated of nonprecious metal (Duceranium U, Dentsply Ceramco) and high-fusing feldspathic porcelain (Duceram Kiss, Dentsply Ceramco). The metal was sandblasted and then acid-etched to roughen the surface to aid in the retention of the resin cement. The bridge was designed to mimic the adjacent tooth and allow the gingival tissue and papilla to appear normal. The height of the papilla is determined by the level of the bone, the patient's biological width, and the size and shape of the gingival



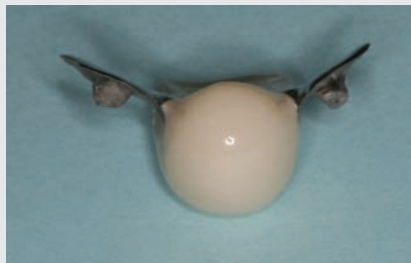**Figure 13**—Shade taking for bridge with Vita 3D tabs.



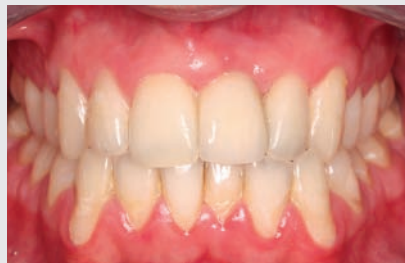**Figure 14**—Lab model with simulated soft tissue; note conservative preparation for bridge at gingulums of incisors only.



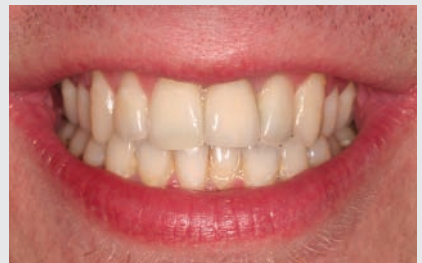**Figure 15**—Bridge; note smooth biconvex contours of tissue side of pontic.



**Figure 16**—Bridge; note retentive extensions on wings of pontic.



**Figure 17**—Three weeks after delivery of bridge; retracted view.



**Figure 18**—Three weeks after delivery of bridge; smile view.

embrasure.<sup>5</sup> In a prosthesis involving a pontic, the papilla can be 6.0 mm to 9.0 mm above the crest of the interproximal bone on the adjacent teeth.<sup>6</sup> A reliable average is 6.5 mm of papilla height when a pontic is used.<sup>7</sup>

In this case, from radiographic evaluation and bone sounding, the interproximal contact point was placed within those parameters. To help position the papilla coronally, keep the gingival embrasure narrow.<sup>5</sup> At the try-in of the bridge, the fit was verified and the pontic was carefully inspected to ensure adequate soft-tissue support. The clinician and patient then evaluated the esthetic qualities of the prosthesis and the patient approved its appearance.

The bridge was bonded in place with OptiBond dental adhesive (Kerr Corporation) with the dual-cure com-

ponent added and Variolink 2 transparent resin cement (Ivoclar Vivadent). Alloy Primer (Kuraray America, Inc) was used to pretreat the metal because it has been demonstrated to increase bond strengths of nonprecious castings to resin up to 34.9 MPa.<sup>8</sup> A dual-cure resin cement and adhesive was chosen over a self-cure because a dual-cure system provides more time to properly seat the prosthesis and to remove excess cement. Furthermore, the abutment teeth are devoid of restorations and are of average thickness (2.0 mm to 4.5 mm). Thus, light transmission through them would be excellent especially because the footprint of the metal wings does not cover a large surface area. This allows access for the curing unit (GC G-Light, GC America, Inc) from numerous locations to ensure sufficient cure of the resin cement and adhesive.

It also should be noted that an opaque, white try-in resin cement was evaluated at the seating appointment, but the abutment teeth appeared no different than with transparent cement. Therefore, because of the concern for adequate light transmission and subsequent cure, the transparent resin was chosen. The seated restoration yielded excellent esthetic results (Figures 17 and 18).

### Conclusion

The most rewarding treatment a dentist can render is one that is functional, esthetic, and satisfies a patient's desires. Whether it is a complete rehabilitation or restoring a single tooth, proper assessment, treatment planning, and selection of procedures is vitally important. In this case, an often overlooked procedure,

the winged-pontic bridge along with soft-tissue development, was successfully used to ultraconservatively and esthetically replace a missing maxillary central incisor. ©

### Acknowledgments

The author would like to thank the lab technicians involved in the fabrication of the removable and fixed prosthetics: France Olenick from Creative Appliances Orthodontic Laboratory, Lemont, Illinois, and Roland B. Tasker from Roland's Dental Ceramics, Lemont, Illinois.

### References

1. Spear FM. The esthetic management of a severe isolated periodontal defect in the maxillary anterior. *Advanced Esthetics & Interdisciplinary Dentistry*. 2006;2(3):19-24.
2. Hebel K, Gajjar R, Hofstede T. Single-tooth replacement: bridge vs. implant-supported restoration. *J Can Dent Assoc*. 2000;66(8):435-438.
3. Morley J. Smile design. Course presented at: Esthetic Dentistry Program, Department of Continuing Dental Education, School of Dentistry, University of Minnesota; January 6, 2006; Minneapolis, Minn.
4. Wilkes PW, Shillingburg HT, Johnson DL. Effects of resistance form on attachment strength of resin-retained castings. *J Okla Dent Assoc*. 2000;90(3):16-25.
5. Spear FM. Interdisciplinary esthetic management of anterior gingival embrasures. *Advanced Esthetics & Interdisciplinary Dentistry*. 2006;2(2):20-28.
6. Salama H, Salama MA, Garber D, et al. The interproximal height of bone: a guidepost to predictable esthetic strategies and soft tissue contours in anterior tooth replacement. *Pract Periodontics Aesthet Dent*. 1998;10(9):1131-1141.
7. Spear FM. The esthetic management of multiple missing anterior teeth. *Advanced Esthetics & Interdisciplinary Dentistry*. 2006;2(1):4-11.
8. Miller MB. Metal Primers. *Reality*. 2006;20:527-529.

### Product References

**Products:** Sensimatic 500SE, SNAP  
**Manufacturer:** Parkell, Inc.  
**Location:** Edgewood, New York  
**Phone:** 800.243.7446  
**Web site:** www.parkell.com

**Products:** Vita Easyshade, 3D shade tabs  
**Manufacturer:** Vident  
**Location:** Brea, California  
**Phone:** 800.828.3839  
**Web site:** www.vident.com

**Products:** Duceranium U, Duceram Kiss  
**Manufacturer:** Dentsply Ceramco  
**Location:** York, Pennsylvania  
**Phone:** 800.487.0100  
**Web site:** www.ceramco.com

**Product:** OptiBond  
**Manufacturer:** Kerr Corporation  
**Location:** Orange, California  
**Phone:** 800.537.7123  
**Web site:** www.kerrdental.com

**Product:** Variolink 2  
**Manufacturer:** Ivoclar Vivadent  
**Location:** Amherst, New York  
**Phone:** 800.533.6825  
**Web site:** www.ivoclarvivadent.us

**Product:** Alloy Primer  
**Manufacturer:** Kuraray America, Inc.  
**Location:** New York, New York  
**Phone:** 800.879.1676  
**Web site:** www.kurarydental.com

**Product:** GC G-Light  
**Manufacturer:** GC America, Inc  
**Location:** Alsip, Illinois  
**Phone:** 800.323.7063  
**Web site:** www.gcamerica.com